



LINC

# Making Sweet Dessert out of the Desert Foot

-

## Pre-recorded Case of the LimFlow Procedure



**Yih Kai Tan MD**  
**Vascular & Endovascular Surgeon**  
**Changi General Hospital**  
**Singapore**



L I N C

## Disclosure

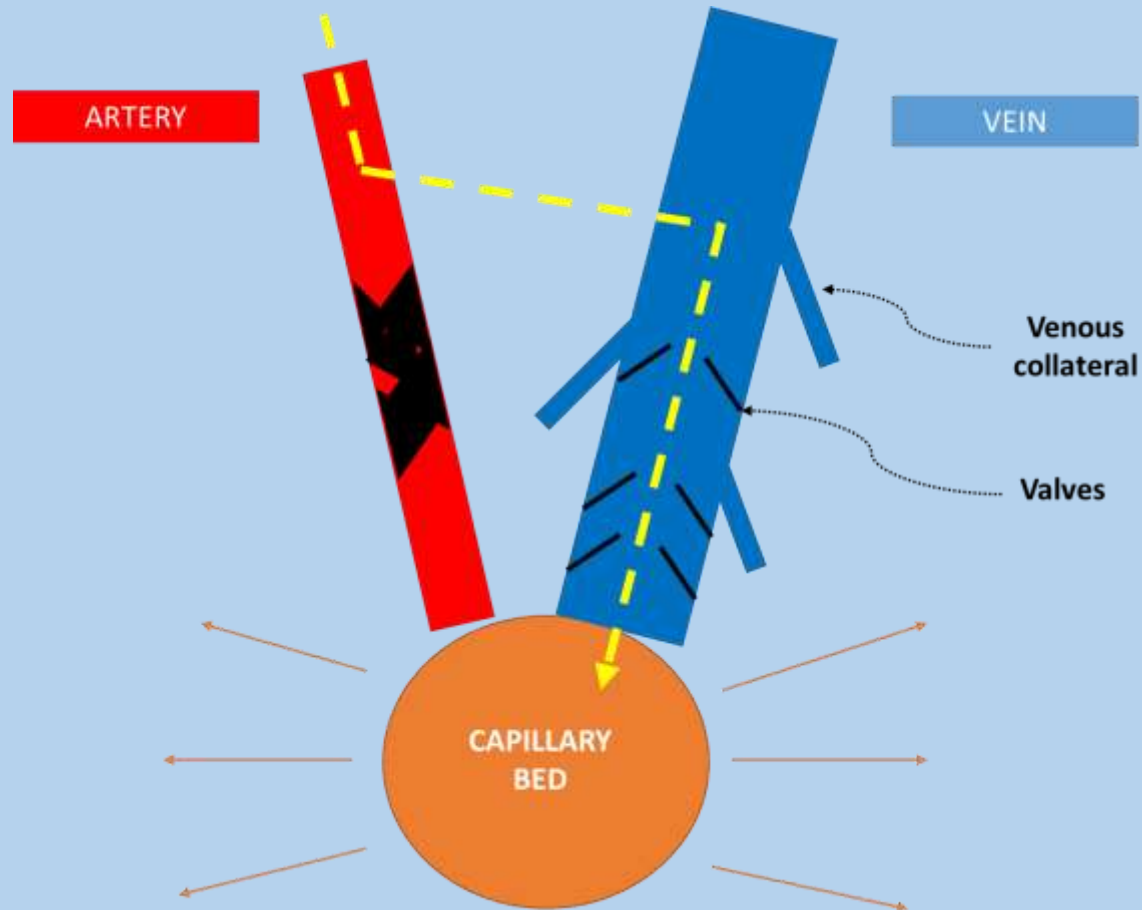
Speaker name:

.....

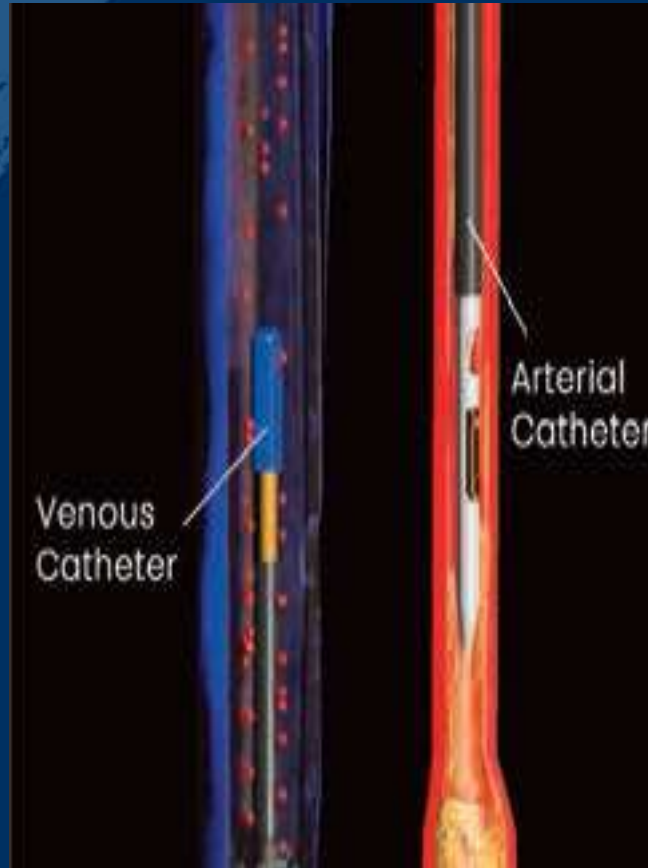
I have the following potential conflicts of interest to report:

- Consulting
- Employment in industry
- Stockholder of a healthcare company
- Owner of a healthcare company
- Other(s)
  
- I do not have any potential conflict of interest

# Concept of Venous Arterialization



7F Sheath arterial crossing ultrasound catheter via downhill technique into a tibial artery



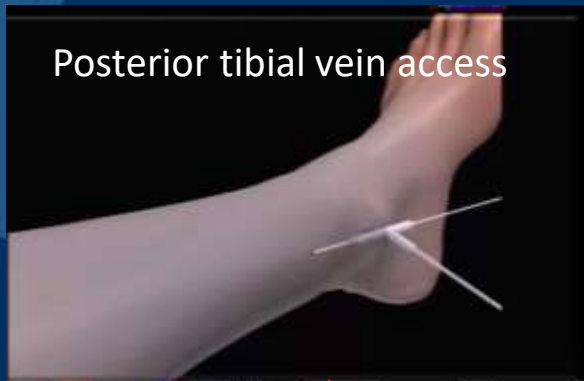Arterial Catheter



Venous Catheter

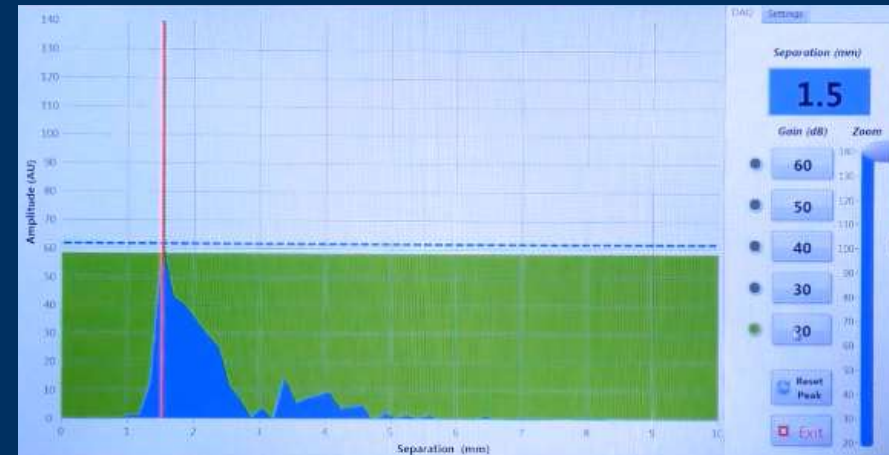
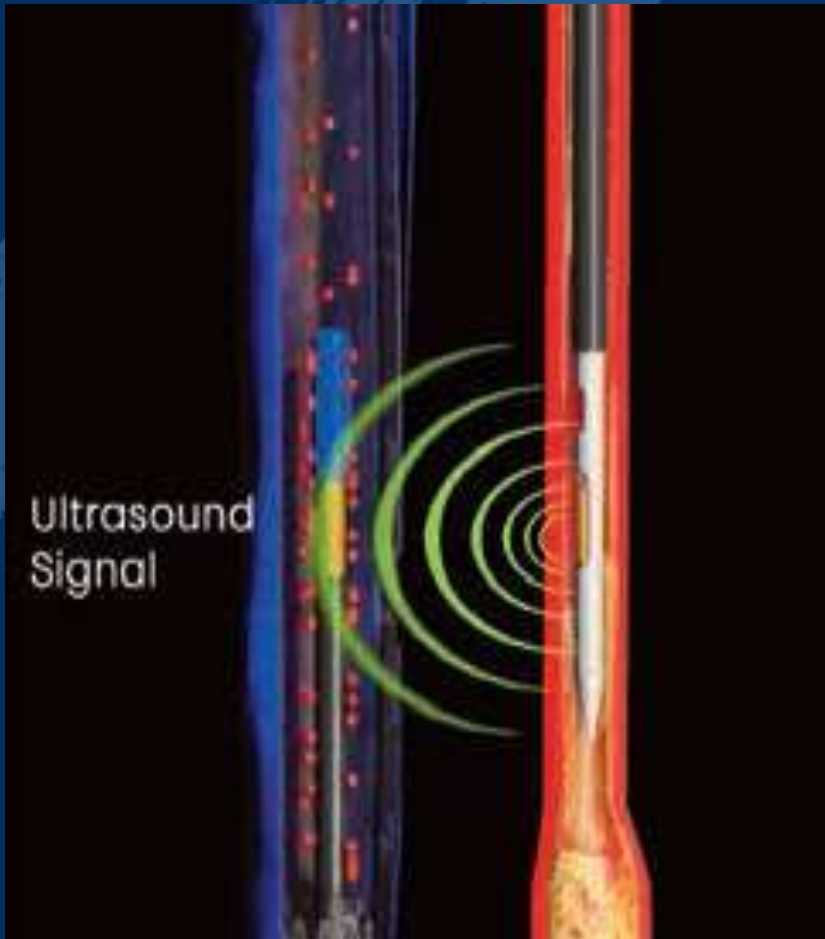


Crossing hollow needle


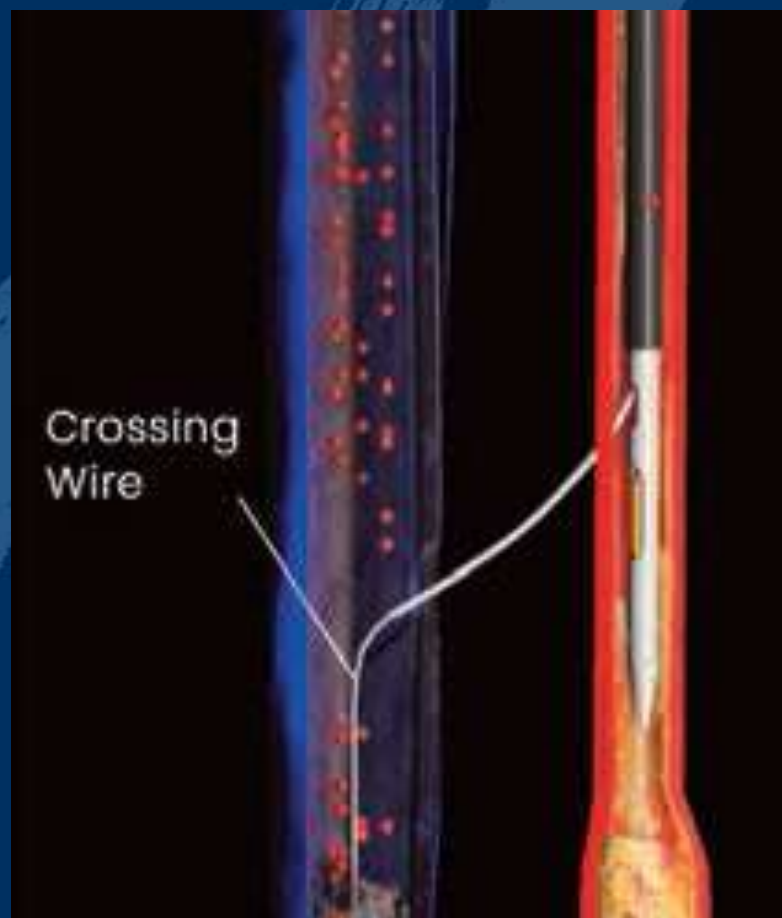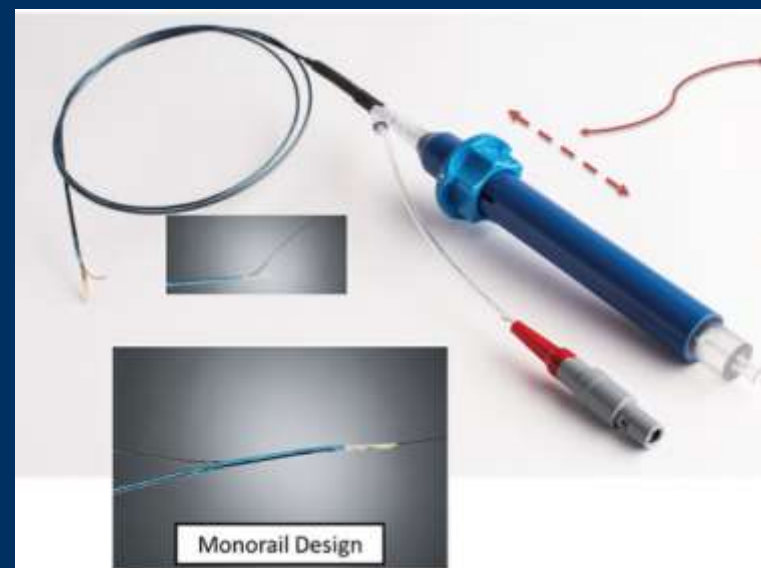


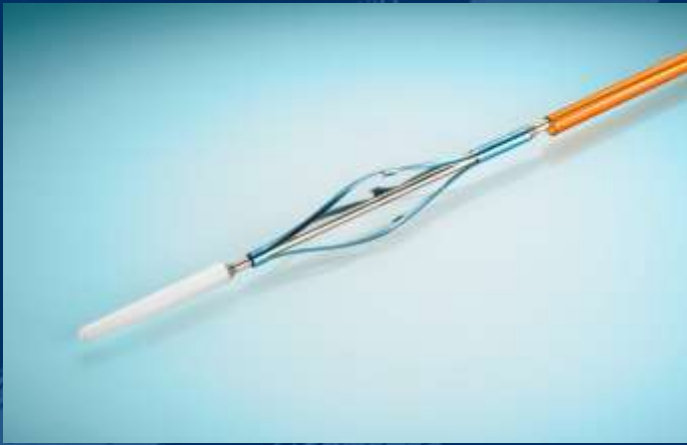
5F Sheath in tibial vein

Venous and Arterial Ultrasound Catheters

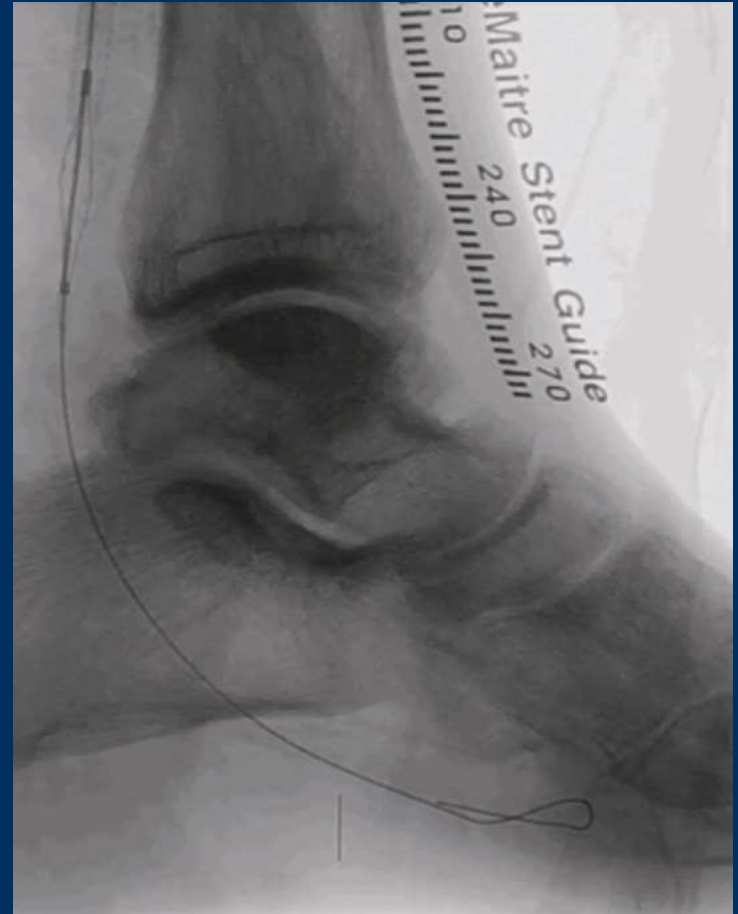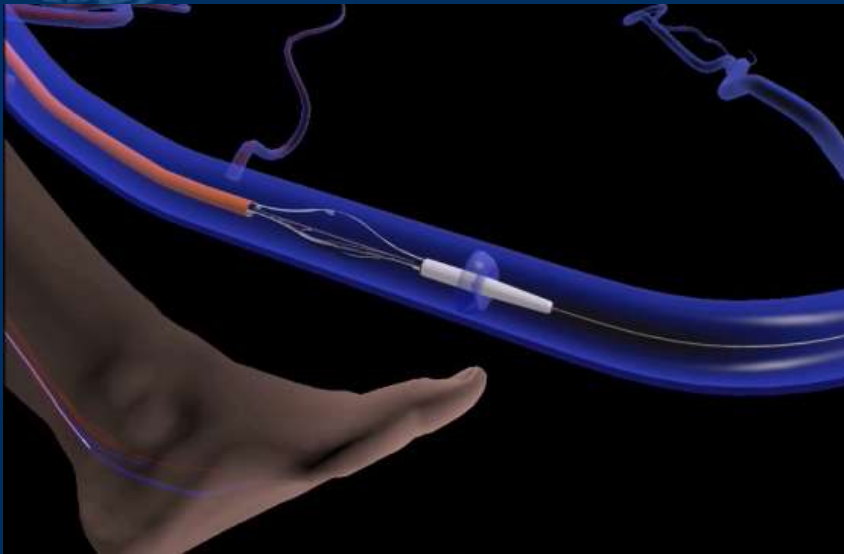


Alignment of the catheters at the chosen crossing point with maximum peak ultrasound signals



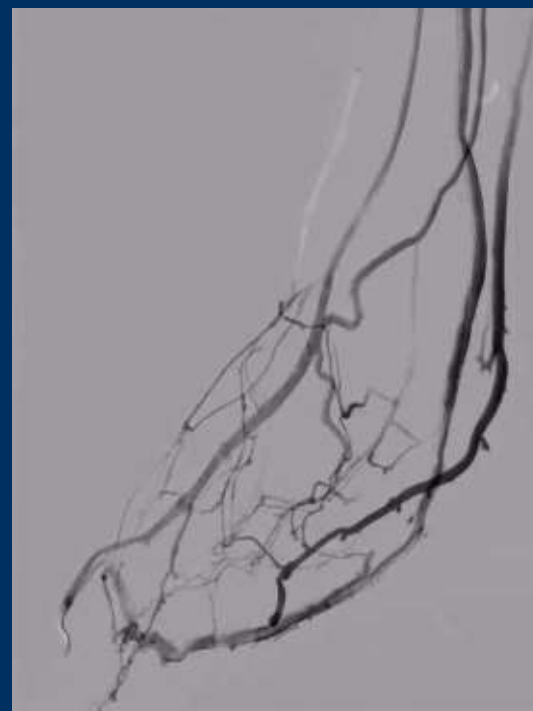

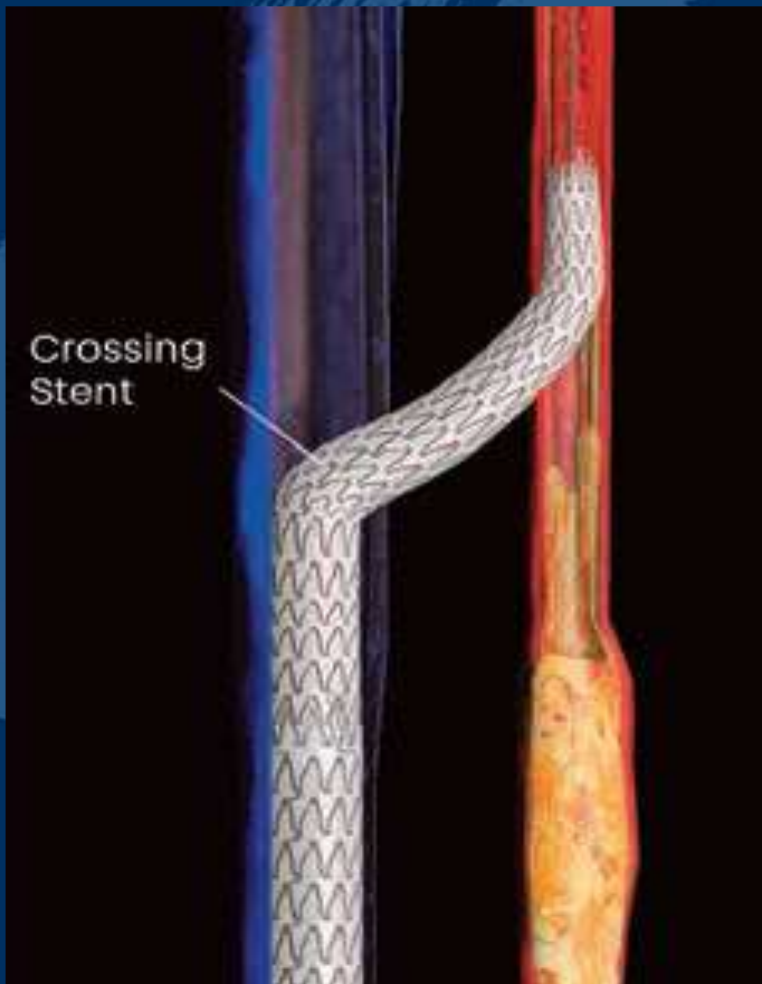


Push Valvulotome (4F OTW)-  
to render valves incompetent



Self-expanding Covered  
Extension Stent

Self-expanding Tapered  
Covered Crossing Stent

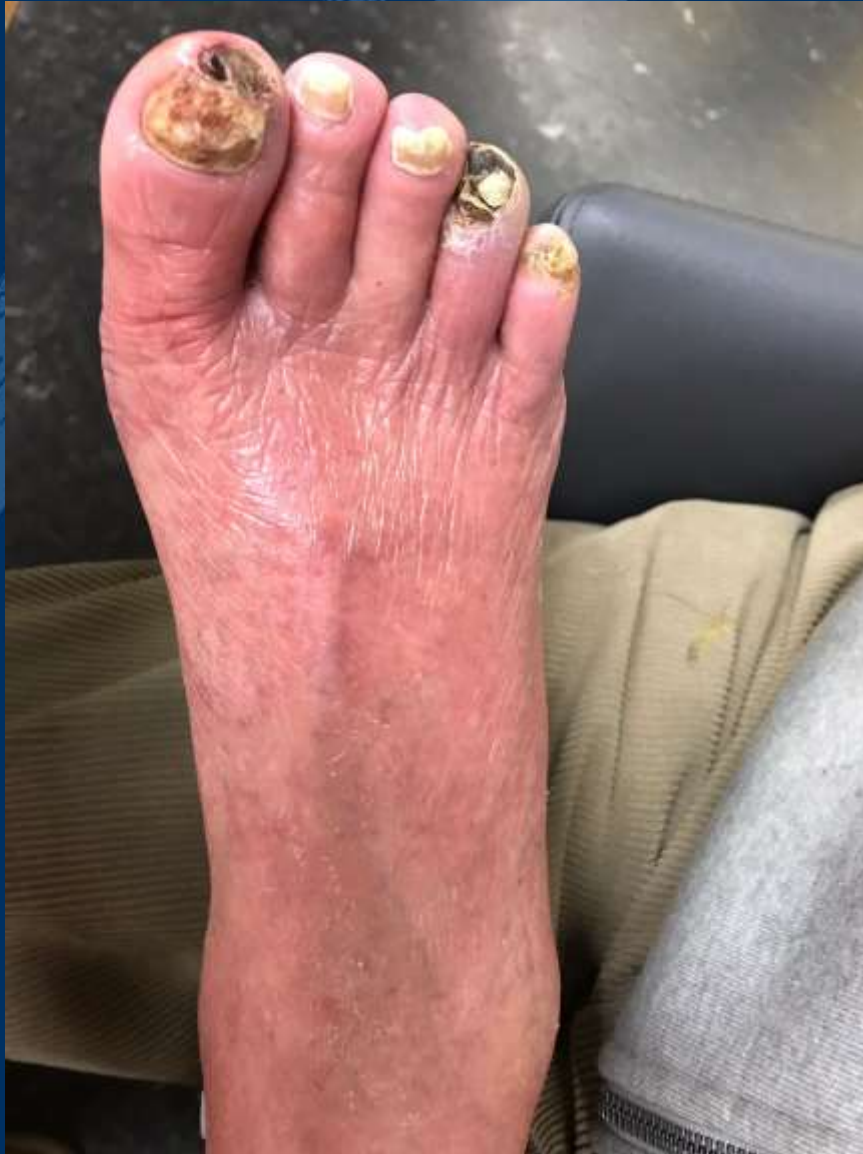




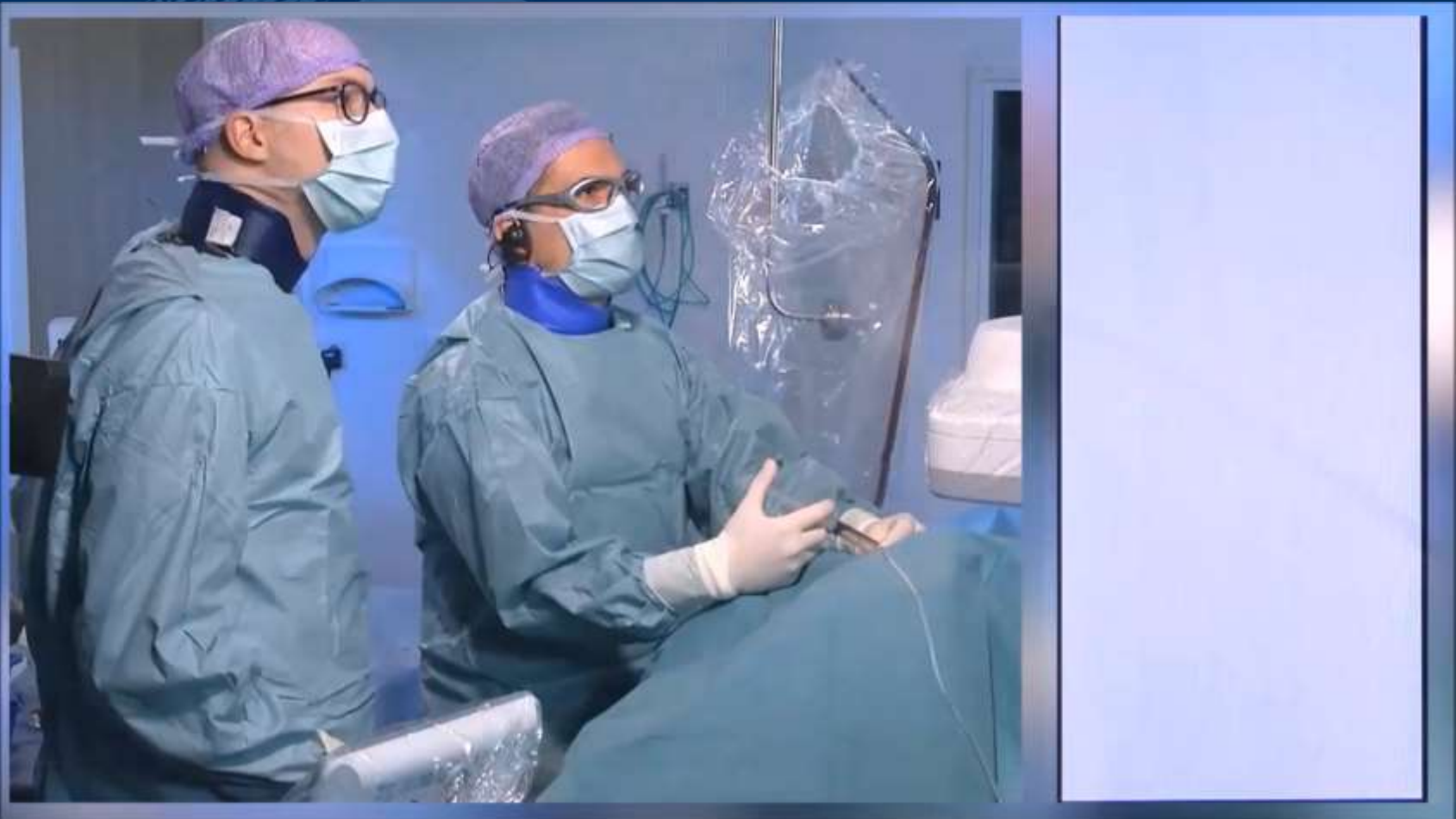
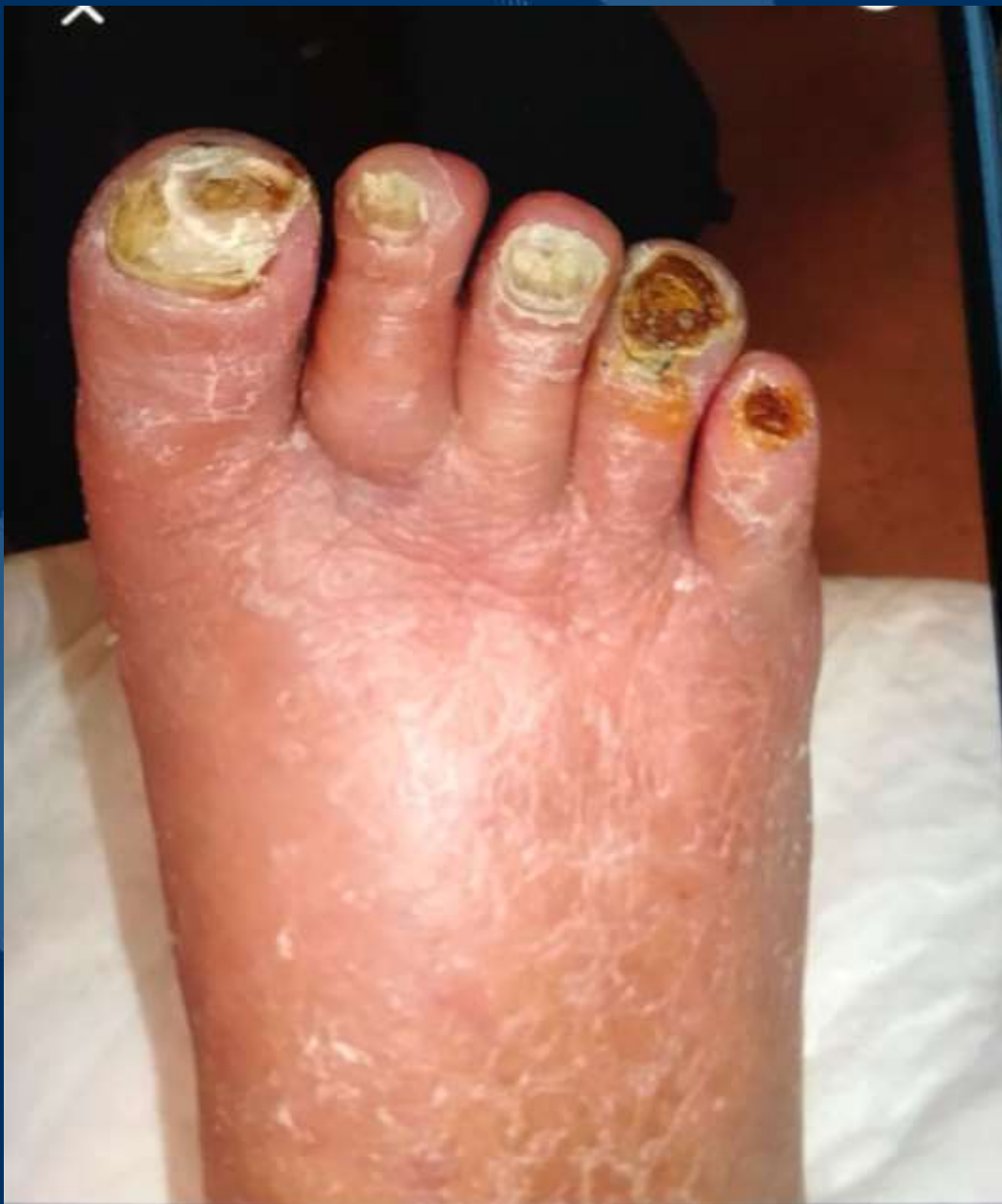**Dr Daniel van Den Heuvel**  
**Interventional Radiologist**

ST ANTONIUS HOSPITAL,  
NETHERLANDS



70 Female  
DM Hypertension  
Ulcers Right 1<sup>st</sup> and 4<sup>th</sup>  
Rutherford 5  
Failed conventional intervention





1 month later

# THANK YOU





LINC

# Making Sweet Dessert out of the Desert Foot

-

## Pre-recorded Case of the LimFlow Procedure



**Yih Kai Tan MD**  
**Vascular & Endovascular Surgeon**  
**Changi General Hospital**  
**Singapore**